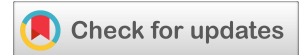

(CASE REPORT)



A rare case of recurrent anemia with giant lipoma of jejunum: A case report

Rina Prasad ^{1,*} and Kamlesh Jaiswal ²

¹ Department of Surgery, Shanti Hospital, Jaunpur, Uttar Pradesh, India.

² Department of Medicine, Shanti Hospital, Jaunpur, Uttar Pradesh, India.

Open Access Research Journal of Science and Technology, 2024, 10(01), 141–144

Publication history: Received on 06 December 2023; revised on 02 February 2024; accepted on 05 February 2024

Article DOI: <https://doi.org/10.53022/oarjst.2024.10.1.0014>

Abstract

Lipoma of the gastrointestinal tract is a rare, benign, usually single, slow growing, non-epithelial neoplasms derived from mature adipocytes.³ The colon is the commonest site of the digestive tract with an incidence rate ~4.4%. Most of the lipomas are asymptomatic and incidentally detected.³ Lipoma should be differentiated from true neoplasia, because in most of the cases they do not need any intervention unless they cause a symptom or are large in size.³ Endoscopic resection is preferred for lipomas < 2cm and surgery for lipomas > 2cm to avoid complication such as bleeding and perforation. We report a case of a 40-year-old male, who was found to have 15cm jejunal lipoma by imaging and confirmed by histopathology.

Keywords: Benign tumours; Gastro-intestinal lipoma; Huge lipoma; Jejunum; Intussusception

1. Introduction

Lipoma of the small intestine is a rare tumor and lipoma of the jejunum is the rarest among gastro-intestinal tract lipoma. Gastrointestinal lipomas are benign, usually single, slow-growing, non-epithelial tumors.¹ The common site is the colon (4.4% incidence), although they may also be found in the stomach, esophagus, and small intestine.³ Asymptomatic lipoma requires only monitoring, whereas symptomatic lipoma requires treatment such as endoscopic or surgical resection. Invasive management is not advised unless complications arise such as intussusception, obstruction, bleeding, or perforation leading to peritonitis.¹

2. Case presentation

A 40-year-old gentleman was admitted to the hospital with recurrent anemia of unknown cause. Five subsequent blood transfusion was done over one year. There was no history of abdominal pain, rectal bleeding, changes in bowel habits, intestinal obstruction symptoms, or melena. On examination, vital parameters were normal. Abdominal examination was normal. On per rectal examination there was no obvious finding. Upper gastro-intestinal endoscopy and lower gastro-intestinal colonoscopy was normal. Stool examination revealed presence of occult blood.

Ultrasound abdomen suggested a well-defined hyper-echoic lesion in the left iliac region with no vascularity in the bowel loop likely lipoma. Contrast-enhanced CT revealed a large fat density lesion (with a maximum axial dimension of 92mm x 35mm) arising from the wall of small bowel loops with ileo-ileal intussusception likely suggestive of lipoma with intussusception.

After excluding surgical contradiction and bowel preparation, explorative laparotomy was done. On exploration a 15 x 5 cm dilated segment of jejunum was seen at a distance of 1 ½ feet distal to the duodeno-jejunal junction. The entire intestine was thoroughly checked for any other pathology. The intestine was resected 3 cm from the upper and lower margin of the mass; it was followed by end-to-end anastomosis.

* Corresponding author: Rina Prasad

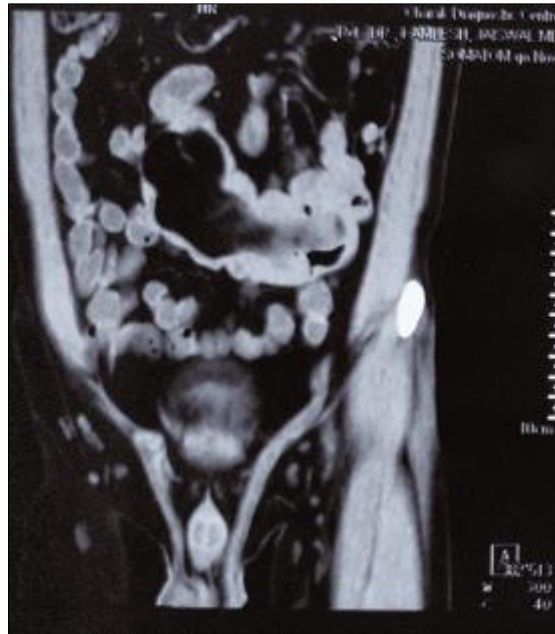


Figure 1 Coronal view of CT abdomen showing a large fat density lesion of 92mm x 35mm in wall of small bowel s/o lipoma

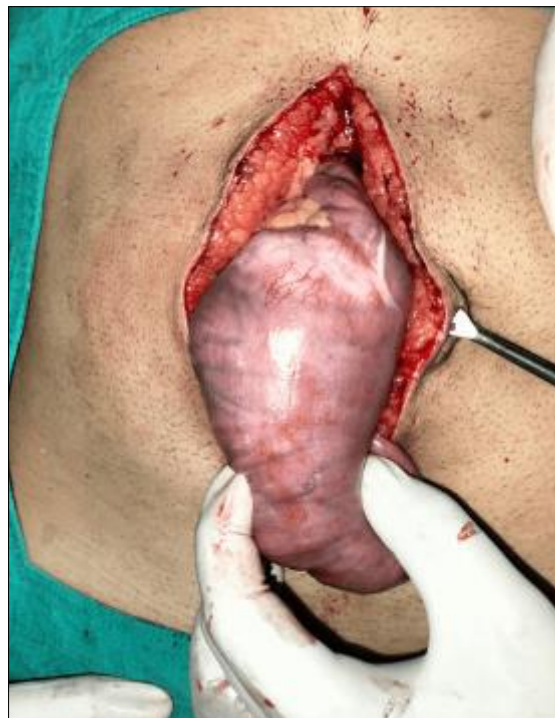

Figure 2 15 x 5 solid mass arising from jejunum on explorative laparotomy

The procedure went smoothly. Externally the lump was soft occupying most of the lumen. The broadest part was proximal and the narrow part distally. There was a narrow passage for the passage of food. On the cut section, a well-defined lobulated mass arising from the antimesenteric border of the jejunum was seen.

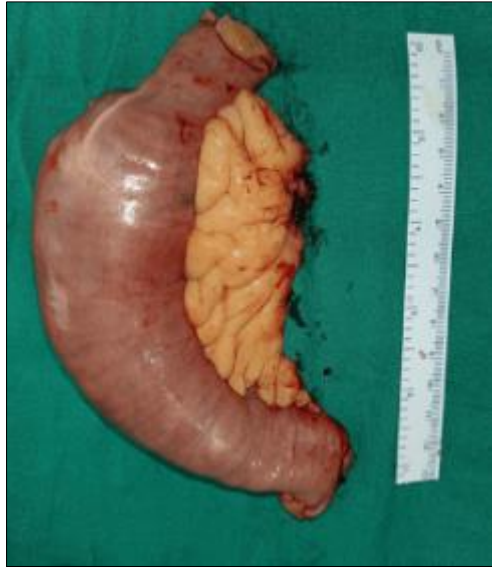

Figure 3 Resected specimen with margin of 3 cm proximal and distal to lump

Histopathological examination reveals submucosal lipoma with ulceration of overlying mucosa, area of fat necrosis and inflammation are seen in lipoma

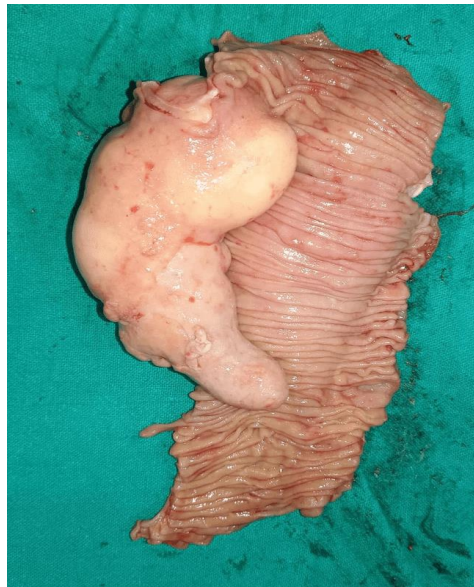

Figure 4 Cut section of specimen. A well lobulated, soft mass arising from anti-mesenteric border jejunum

3. Discussion

Gastrointestinal lipoma is a benign tumor of mesenchymal origin. The incidence of gastro-intestinal lipoma is reported up to 5%. Incidence is highest in the colon (65-75%); followed by the small intestine (20-25%) and very rarely in the esophagus and stomach.

Most lipomas are asymptomatic but sometimes produce symptoms likely GI bleeding, intussusception, or obstruction.³ Large lipomas (>2cm) are most likely to cause symptoms, so they may be mistaken for malignant lesions.³

CT is the most valuable diagnostic method for intestinal lipoma. It can reveal the typical characteristics of uniform tumor density and fat density, allowing for a definite diagnosis. A CT scan may also reveal associated intussusception if present.³

Asymptomatic lipoma needs no treatment. Symptomatic lipoma usually requires surgical intervention. The localized, small, solitary lipoma can be easily and safely removed using Endoscopic mucosa resection (EMR), Endoscopic mucosal resection- after Pre-cutting (EMR-P), and Endoscopic mucosal dissection (EMD). Surgical resection is recommended in patients with multiple or large lipomas.⁴

4. Conclusion

Recurrent anaemia with occult blood in stool should be thoroughly evaluated. Asymptomatic GI lipoma need no intervention. Lipoma < 2 cm should be managed endoscopically, while lipoma >2cm need surgical intervention.

Compliance with ethical standards

Disclosure of conflict of interest

No conflict of interest to be disclosed.

References

- [1] Lee KJ, Kim GH, Shin NR, Lee BE, Ryu DY, Kim DU, Am Song G. Endoscopic resection of gastrointestinal lipomas: a single-center experience. *Surgical endoscopy*. 2014; 28(1):185-92.
- [2] Jiang RD, Zhi XT, Zhang B, Chen ZQ, Li T. Submucosal lipoma: a rare cause of recurrent intestinal obstruction and inte
- [3] Aya N Farfour, Noor A Abu Omar, Fahad I Alsohaibani Large lipoma of the ascending colon: a case report and review of literature <https://doi.org/10.1093/jscr/rjaa354>
- [4] Kwang Jae Lee¹, Gwang Ha Kim, Do Youn Park, Na Ri Shin, Bong Eun Lee, Dong Yup Ryu, Dong Uk Kim, Geun Am Song Endoscopic resection of gastro-intestinal lipomas: A single-centre experience